

## **Influence of butyric acid supplemented diets on growth response, precaecal nutrient digestibility, gut morphology and histopathological measurements in broiler chickens**



\*Agboola, A. F., Omidiwura, B. R. O., Ahmed, R. O. and Ayoola, O. D.

Department of Animal Science, University of Ibadan, Ibadan, Nigeria

\* Corresponding author: adebisi.agboola@gmail.com; +234(8)022004830

### **Abstract**

*In recent time, there has been call for antibiotics substitute in animal feed due to concerns over its residual effects and the development of antibiotic-resistant bacteria in humans consuming the meat. Short chain fatty acids are often used as viable alternatives to antibiotics. However, there has conflicting reports on the efficacy of the organic acids. This study was therefore aimed at assessing the effects of butyric acid supplemented diets on growth performance, ileal nutrient digestibility, gut morphology and histopathology of broiler chickens in a 21-day feeding trial. Three hundred and thirty-six, one-day old Arbor Acre plus broiler chicks were randomly assigned to seven dietary treatments with six replicate groups of eight chickens each. Diet 1 was the Corn-SBM diet {basal diet (negative control NC)}; Diet 2 (positive control) was basal diet+105g of oxytetracycline/tonne of feed; Diet 3 comprised NC+0.1% butyric acid; Diet 4 consisted of NC+ 0.2% butyric acid, Diet 5 contained NC+ 0.3% butyric acid, Diet 6 had NC+ 0.4% butyric acid and Diet 7 consisted of NC+ 0.5% butyric acid. Titanium dioxide was added at the rate of 5g/kg as indigestible dietary marker. Performance indices were calculated. On day 21, two chickens per replicate were slaughtered, excised and digesta samples collected at two-thirds to ileo-caeco-colonic junction for digestibility assay. After flushing out the digesta samples, sections of the ileum (5cm posterior to Meckel's diverticulum) were removed for ileal morphological measurements while ileal sections and liver were harvested for histopathological examinations. There were no significant ( $P>0.05$ ) differences in the performance indices across the treatments. Digestibility of crude protein, ash and nitrogen free extract in broiler chickens fed diets containing antibiotic and 0.2, 0.3, 0.4 and 0.5% butyric acid supplemented diets were significantly ( $P<0.05$ ) higher than those fed basal diet and diet supplemented with 0.1% butyric acid. Ether extract digestibility of those fed basal diet was similar ( $P>0.05$ ) to chickens on other dietary treatments. Similar crude fibre digestibility was recorded for basal diet and 0.1% butyric acid supplemented diet. Diets had no significant influence on the villus length, villus height, crypt depth, epithelial thickness and villus height to crypt depth ratio. Histopathological observation of chickens on the control diet showed clinical symptoms of villi and hepatocellular atrophy. No lesions were observed in the ilea of chickens on the antibiotics supplemented diets. Clinical symptoms ranging from villi atrophy, necrosis of the villi, clubbing of the villi, loss of enterocyte, hepatocellular atrophy and necrosis, hyperplasia of bile ductular epithelium, accentuation of sinusoids, and focus of lymphoid aggregate in parenchyma of liver were observed for chickens on butyric acid supplemented diets. Due to the equal level of performance recorded across treatments, it may therefore be concluded that using butyric acid up to 0.5% in diet can replace antibiotic usage but had no comparative beneficial effect on broiler productivity at 21 days.*

**Keywords:** Butyrate, Performance, Gut morphometric, Ileal nutrient digestibility, Broiler chickens

### **Introduction**

Evidence has been mounting that antibiotic-resistant enterpathogenic bacteria can

transfer from animals to man via the food chain or by direct contact, leading to the establishment of community reservoir of

resistant genes (Van den Bogaard and Stobberingh, 1999; Leeson, 2007). Although, low-level antibiotics additives added to livestock diets can help prevent illness and improve performance, but their prolonged use has the potential to increase bacteria resistance and the level of drug residues in edible animal by-products, leading to the transfer of antibiotic resistance to human pathogens with its resultant consequences to human health (Kritas and Morrison, 2005). Several feed additives such as organic acids, probiotics, prebiotics, symbiotics have been used as alternative growth promoters in poultry production (Biggs and Parsons, 2008; Panda *et al.*, 2009 and Agboola *et al.*, 2014). Among the organic acids, short chain fatty acids (acetic, butyric and propionic acids) have been reported to have positive impact on growth performance in broiler chicken (Hassan *et al.*, 2010). Similarly, Kumar *et al.* (2010) reported that organic acid supplementation enhances intestinal absorption by increasing villi growth in height and width. These acids have been reported to exhibit antimicrobial properties by reducing intestinal pH when dissociated (Van Immerseel *et al.*, 2006). It has been shown that microflora has significant impact on host nutrition, health and growth performance by interacting with nutrients consumed and also playing a role in the development of the host's gut system (Garrido *et al.*, 2004). Despite the advances made, there has been no clear-cut suggestion on the specific level of butyric acid inclusion that will successfully replace antibiotics and give optimum performance. Therefore, the aim of this study was to evaluate the effects of butyric acid supplemented diets on growth performance, precaecal nutrient digestibility, gut morphology and histopathology of broiler chickens.

## **Materials and methods**

### ***Experimental site***

This study was carried out at the Poultry Unit of the Teaching and Research Farm, University of Ibadan, Oyo State in the South West geopolitical zone of Nigeria, within the tropical rain forest region.

### ***Experimental diets and management of chickens***

Three hundred and thirty-six, one-day-old Arbor Acre plus broiler chicks of average initial weight of 43g were obtained from a reputable local commercial poultry farm in Ibadan. The chickens were tagged, weighed and allocated to 42 pens each with 8 chickens per pen. Six replicate pens were then randomly allotted to each of the 7 dietary treatments in a completely randomized design. The chickens were reared in a well-ventilated and illuminated standard poultry house in a study lasted for 21 days. There were seven experimental treatments; Diet 1 was the Corn-SBM diet {basal diet (negative control NC)}; Diet 2 (positive control) was basal diet+105g of oxytetracycline/tonne of feed; Diet 3 comprised NC+0.1% butyric acid; Diet 4 consisted of NC+ 0.2% butyric acid, Diet 5 contained NC+ 0.3% butyric acid, Diet 6 had NC+ 0.4% butyric acid and Diet 7 consisted of NC+ 0.5% butyric acid. Feed and water were supplied *ad libitum*. The feed (Table 1) was formulated to meet the nutrient requirements of the chickens according to the recommendations of NRC (1994).

### **Data collection**

#### **Parameters measured and calculated**

The weekly feed intake calculated as the difference between feed supplied and leftovers. The weekly weight gain was obtained by subtracting the initial weight from the final weight. Feed conversion ratio was calculated as the ratio of feed intake to

**Table 1: Gross composition (g/kg) of Experimental diets (Broiler starter 0-21days)**

INGREDIENTS g/kg	Negative control (NC)	Positive control (PC)	NC+0.1% BA	NC+0.2% BA	NC+0.3% BA	NC+0.4% BA	NC+0.5% BA
<b>Diet</b>							
Corn	555.00	555.00	555.00	555.00	555.00	555.00	555.00
Soyabean meal	370.00	370.00	370.00	370.00	370.00	370.00	370.00
Fish meal	25.00	25.00	25.00	25.00	25.00	25.00	25.00
Wheat Offal	13.00	13.00	13.00	13.00	13.00	13.00	13.00
Dicalcium phosphate	17.00	17.00	17.00	17.00	17.00	17.00	17.00
Premixes	2.50	2.50	2.50	2.50	2.50	2.50	2.50
Limestone	10.00	10.00	10.00	10.00	10.00	10.00	10.00
Methionine	2.50	2.50	2.50	2.50	2.50	2.50	2.50
Lysine	2.50	2.50	2.50	2.50	2.50	2.50	2.50
Salt	2.50	2.50	2.50	2.50	2.50	2.50	2.50
Antibiotics	0.00	0.11	0.00	0.00	0.00	0.00	0.00
Butyric acid	0.00	0.00	1.00	2.00	3.00	4.00	5.00
<b>TOTAL</b>	<b>1000</b>	<b>1000</b>	<b>1000</b>	<b>1000</b>	<b>1000</b>	<b>1000</b>	<b>1000</b>
<b>CALCULATED NUTRIENTS (g/kg)</b>							
Crude protein	231.11	231.11	231.11	231.11	231.11	231.11	231.11
Energy ME, kcal/kg	3000.68	3000.68	3000.68	3000.68	3000.68	3000.68	3000.68
Fat	36.85	36.85	36.85	36.85	36.85	36.85	36.85
Crude fibre	39.39	39.39	39.39	39.39	39.39	39.39	39.39
Calcium	9.92	9.92	9.92	9.92	9.92	9.92	9.92
Total phosphorus	7.69	7.69	7.69	7.69	7.69	7.69	7.69
NPP	4.28	4.28	4.28	4.28	4.28	4.28	4.28
Ca:NPP	2.31	2.31	2.31	2.31	2.31	2.31	2.31

Composition of premix per kg of diet: Vitamin A, 12500 I.U; vitamin D3, 255000 I.U; vitamin K3, 2mg; vitamin B1, 3mg; vitamin B2, 5.5mg; calcium pantothenate, 11.5mg; vitamin B12, 0.025mg; choline chloride, 500mg; folic acid, 1mg; biotin, 0.08mg; manganese, 120mg; iron, 100mg; zinc, 80mg; copper, 8.5mg; iodine, 1.15mg; cobalt, 0.3mg; selenium 0.12mg; anti-oxidant, 120mg. Titanium dioxide was added to experimental diets at the rate of 5g/kg as indigestible dietary marker. NPP–Non-phytate phosphorous, Ca – Calcium, PC–Positive control NC–Negative Control BA–Butyric Acid

weight gained.

### Nutrient digestibility

#### Digesta collection

On day 21, two chickens per replicate were weighed and their final body weight recorded after which they were sacrificed and eviscerated. Digesta was collected at the two-thirds terminal of the section between Meckel diverticulum and 2cm anterior to the ileo-caeco-colonic junction of the chickens as described by Agboola (2011). The contents were flushed out with distilled water, pooled according to replicates and frozen. The frozen samples were then freeze-dried and grinded for further analysis and subsequently used for digestibility calculation.

### Digestibility calculations

Apparent precaecal CP digestibility was

$$D_{CP}(\%) = 1 - \left( \frac{TiO_2 \text{ diet}}{TiO_2 \text{ digesta}} \right) \times \left( \frac{CP \text{ digesta}}{CP \text{ diet}} \right) \times 100$$

Where:

$D_{CP}$  = % apparent precaecal crude protein digestibility

$TiO_2 \text{ diet}$  = concentration of titanium dioxide in the diet (%)

$TiO_2 \text{ digesta}$  = concentration of titanium dioxide in the digesta (%)

$CP \text{ digesta}$  = concentration of crude protein in digesta (%)

$CP \text{ diet}$  = concentration of crude protein in diet (%)

***Gut morphological measurements and histopathological examinations***

On day 21, two chickens per replicate were sacrificed by cervical dislocation. From each of the bird, about 2 cm segment from the last two-third portion of the ileum from the ileo-caeco-colonic junction was excised and flushed with distilled water. Ileal sections were collected from each group of bird in a replicate and the samples were kept in pre-labelled polyvinyl bottle filled with 10% buffered formalin for preservation.

***Tissue Processing***

According to the method of Iji *et al.* (2001), the tissues were allowed to fix in 10% formal saline for 48 hours. The tissues were grossed and cut into smaller pieces of 3mm thick in pre labelled tissue cassette. They were processed using Automatic Tissue Processor (LEICA TP1020) where they passed through various reagents including Alcohol (of various concentrations starting from 70%, 80%, 90%, 95%, and two 100% or Absolute alcohol) for dehydration, two changes of Xylene and three changes of molten Paraffin wax set at 65 °C. The processing time was 12 hours.

***Embedding***

The tissues were embedded in Paraffin wax by burying in a metal mold containing molten paraffin wax and allowed to form paraffin blocks, ready for microtomy.

***Microtomy (sectioning)***

The tissues were sectioned at 4microns using Rotary microtome (LEICA RT2115) and the sections were floated on hot water bath to attach the sections to pre-labelled slides. The sections were dried on hot plate and ready for staining using Haematoxylin and Eosin Staining Technique before periodic acid Schiff reaction.

***Histomorphometry***

The slides of tissues of the were examined under the light microscope at x400 magnification and the following

histomorphometric measurements were taken with the aid of the graticle in micrometers (%m) and the multiplication factor of 0.138305755: villus height, crypt depth, villus length, and epithelial thickness.

***Histopathology***

The appropriately labelled samples (ileum and liver) were subjected to the following procedure. Dissected and appropriately labelled, fixed in 10% neutral buffered formalin for further fixing before processing in an automatic tissue processor, embedded in paraffin wax and sectioned at 5 microns on rotary microtome mounted on glass slides. After sectioning, the sections were floated on lukewarm water in a floatation bath for stretching and then the paraffin sections were mounted on slides using an egg albumin and dried on slide warmer. The sections were then stained with standard Heamatoxylin and Eosin solution for general microscopic study.

***Examination and Description of microscopic specimens***

Examination of slide (section) by the naked eye, then thorough examination of whole section using low power (x4) objective lens (of Olympus microscope camera) so as to appreciate the main structural patterns and identification of normal tissue, Abnormal areas were subjected to further examination still under low power and medium power (x10) objective and doubtful cells or structures were further examined under higher (x40) objective lens.

***Description***

Normal tissues were identified. The pathological changes observed in the microscopic examination were described accordingly based on histological structure of the tissues. Photomicrographs were taken with the aid of computerized digital camera.

***Chemical analysis***

The proximate composition of the diet was determined by the methods of AOAC

(2000).

### **Statistical analysis**

Data were analyzed using the analysis of variance (ANOVA) of SPSS (Version 20.0) and means separated using Duncan's Multiple Range Test. The chosen level of significance for all comparison was  $P < 0.05$ .

### **Results**

#### ***Growth performance indices of broiler chicks fed butyric acid supplemented diets***

Proximate composition of experimental diets is shown in Table 2. Crude protein, crude fibre, ether extract and ash were 22, 4.3, 7.4, 6.4%, respectively. The result of the effect of dietary supplementation with antibiotic growth promoter and butyric acid on growth performance of broiler chicken is presented in Table 3. The results showed that there were no significant ( $P > 0.05$ ) differences in the daily and weekly (week one to three) weight gains across all treatments. Similarly, diets had no significant ( $P > 0.05$ ) effects on final weights. Feed conversion ratio of chickens on experimental diets were not significantly ( $P > 0.05$ ) different.

#### ***Nutrient digestibility of broiler chickens fed butyric acid supplemented diets***

The result of nutrient digestibility of broiler chickens fed antibiotics and butyric acid supplemented diets is shown in Table 4. Digestibility of crude protein, ash and nitrogen free extract in chickens fed diets containing antibiotic and 0.2, 0.3, 0.4 and 0.5% butyric acid supplemented diets were significantly ( $P < 0.05$ ) higher than those fed

basal diet and diet supplemented with 0.1% butyric acid. Ether extract digestibility for basal diet was similar to chickens on other dietary treatments. Similar crude fibre digestibility was recorded in chickens fed basal diet and 0.1% butyric acid supplemented diet.

#### ***Gut morphological parameters of broiler chicks fed antibiotics and butyric acid supplemented diets***

The result of the gut morphology of broiler chicken fed dietary antibiotics and butyric acid supplemented diets is presented in Table 5. Diets had no significant influence on the villus length, villus height, crypt depth, epithelial thickness and villus height to crypt depth ratio.

#### ***Histopathological readings of the Ileum and liver of broiler chicks fed butyric acid supplemented diets***

Microscopic images displaying the histopathological observation of the ileum and liver are presented in plates 1 – 14 below.

### **Discussion**

#### ***Performance of broiler chicks fed antibiotics and butyric acid supplemented diets***

Results of the present study showed that butyric acid supplementation in the diet of broiler chicken had no significant effect on their growth performance in the starter phase. Final weight (at 21 days) of chickens on all levels of butyric acid were not different from those on the antibiotics and the basal diets. Similar observations were recorded for weight gain, feed intake and

**Table 2: Proximate composition (g/100gDM) of experimental diet**

Parameters	Value (%)
Dry matter	91.2
Crude protein	22
Crude fibre	4.3
Ether extracts	7.4
Ash	6.4
Nitrogen free extract	59.9

Table 3: Growth performance indices of broiler chicken fed butyric acid supplemented diets (d 0-21)

Parameters	NC (Basal diet)	PC (antibiotics)	NC+0.1% BA	NC+0.2% BA	NC+0.3% BA	NC+0.4%BA	NC+0.5% BA	P value
Initial weight(g/b)	42.97±0.05	43.01±0.04	43.16±0.07	42.96±0.03	43.01±0.08	43.03±0.06	42.99±0.08	0.385
Final weight (g/b)	359.28±7.51	368.20±10.67	379.16±16.98	378.33±9.16	375.02±5.26	378.40±11.00	367.23±13.06	0.833
Week 1 WG (g/bird)	60.98±2.56	62.38±1.97	62.98±1.62	58.00±3.08	58.00±3.08	59.82±1.78	61.15±1.67	0.683
Week 2 WG (g/bird)	127.78±6.93	120.99±7.01	128.66±4.16	128.43±2.30	127.42±5.87	134.15±3.40	131.81±6.02	0.743
Week 3 WG (g/bird)	165.26±11.75	154.50±11.80	159.73±11.44	150.32±5.47	151.76±4.18	159.76±6.54	141.68±8.19	0.629
Feed intake(g/b/d)	23.36±1.01	21.77±0.40	22.56±0.61	22.26±0.50	22.56±0.79	22.46±1.70	23.45±1.49	0.807
FWG (g/bird/day)	15.06±0.36	15.49±0.51	16.00±0.80	15.97±0.44	15.81±0.25	15.97±0.52	15.44±0.62	0.830
FCR	1.56±0.08	1.41±0.05	1.42±0.07	1.40±0.05	1.43±0.05	1.41±0.05	1.52±0.05	0.364

Means in the same row are not significantly ( $P>0.05$ ) different

NC= Negative Control, PC= Positive Control, BA= Butyric acid, WG= Weight gain, FCR= Feed Conversion Ratio FWG=Final weight gain



**Table 4: Precaecal apparent nutrient digestibility of broiler chicken fed butyric acid supplemented diets (d 0-21)**

Parameters	NC	PC	NC+0.1% BA	NC+0.2% BA	NC+0.3% BA	NC+0.4 BA	NC+0.5% BA	P value
CP digestibility	69.09±2.31 <sup>b</sup>	81.70±5.86 <sup>a</sup>	62.97±2.99 <sup>b</sup>	82.35±2.36 <sup>a</sup>	86.73±0.83 <sup>a</sup>	85.32±0.88 <sup>a</sup>	88.929±1.20 <sup>a</sup>	<0.0001
EE digestibility	90.90±1.10 <sup>ab</sup>	94.61±1.94 <sup>a</sup>	79.34±1.04 <sup>b</sup>	95.76±0.39 <sup>a</sup>	96.82±0.45 <sup>a</sup>	95.70±0.37 <sup>a</sup>	96.81±0.43 <sup>a</sup>	0.1186
CF digestibility	77.24±1.66 <sup>bc</sup>	84.41±5.95 <sup>ab</sup>	73.13±1.70 <sup>c</sup>	87.73±1.14 <sup>a</sup>	90.86±0.69 <sup>a</sup>	89.34±0.30 <sup>a</sup>	90.98±0.26 <sup>a</sup>	<0.0001
Ash digestibility	26.77±2.63 <sup>b</sup>	58.57±6.07 <sup>a</sup>	18.83±3.81 <sup>b</sup>	57.45±3.98 <sup>a</sup>	66.69±2.79 <sup>a</sup>	66.00±1.10 <sup>a</sup>	65.19±5.18 <sup>a</sup>	<0.0001
NFE digestibility	30.89±3.60 <sup>b</sup>	62.12±8.45 <sup>a</sup>	19.98±5.21 <sup>b</sup>	61.79±2.94 <sup>a</sup>	73.07±1.82 <sup>a</sup>	70.97±0.51 <sup>a</sup>	73.30±3.34 <sup>a</sup>	<0.0001

NC= Negative Control, PC= Positive Control, BA= Butyric acid, CP= Crude protein, EE= Ether extract,

CF= Crude Fibre, NFE= Nitrogen free extract.

Means on the same row having different superscript are significantly different (P<0.05).

**Table 5: Gut morphological characteristics of broiler chicks fed antibiotics and butyric acid supplemented diets**

Parameters	NC (Basal diet)	PC (antibiotics)	NC±0.1% BA	NC±0.2% BA	NC±0.3% BA	NC±0.4% BA	NC±0.5% BA	P value
Villus length (µm)	820±80.29	793.3±17.64	886.7±83.53	806.7±109.14	833.33±29.06	860±64.29	920±40.00	0.833
Villus height (µm)	1177.78±28	866.7±38.49	1222.2±41.86	1055.6±85.99	1166.7±66.67	1022.2±29.39	1111.1±62.70	0.764
Crypt depth (µm)	313.33±17.64	233.33±17.64	273.33±24.04	313.33±17.64	273.33±17.64	273.33±43.72	253.33±6.67	0.285
VH:CD	3.72±0.73	3.74±0.21	4.45±0.12	3.91±0.38	4.33±0.54	3.95±0.65	4.35±0.95	0.826
Villi width (µm)	240.00±30.55	213.33±6.67	253.33±6.67	266.67±18.59	240.00±11.55	220.00±34.64	266.67±6.67	0.892
Epithelial thickness (µm)	111.11±11.11	144.44±29.39	99.99±0.00	133.33±19.24	111.11±11.11	99.99±0.00	111.11±6.64	0.111

Means along the same row with no superscripts are not significantly ( $P>0.05$ ) different.

VH: Villus height CD: Crypt depth



feed conversion ratio of chickens on experimental diets. Daily and weekly weight gain were also not different across all treatments. It also indicated that using butyric acid as a diet supplement had no significant effect on feed intake and feed conversion ratio. The result agrees with the findings of Leeson *et al.* (2005) that butyric acid inclusion at 0.2 or 0.4% had no effect on body weight or weight gain of broiler chickens. It also conforms with the work of Mahdavi and Torki (2009) that 0.2 and 0.3% dietary inclusion of butyric acid had no clear effect on performance of broiler chicken. Organic acids, like antibiotics are more growth permitting than growth promoting in the sense that they can only permit the animal to grow to its genetic potentials irrespective of the plane of nutrition. (Alp *et al.*, 1999; Dibnac and Buttin, 2002 and Gunal *et al.*, 2006). The present study also conforms with findings of Aghazadeh and Tahayazdi (2012) who concluded that dietary supplementation with butyric acid (at 0.1 and 0.25%) had no effect on average weight gain or feed conversion ratio in the starter, grower/finisher and over whole (0 –42 d) trial periods. It was also reported that butyric acid had no significant effect on weight gain in the grower/finisher period (21–42days). Adil *et al.* (2011) also reported no significant body weight gain difference between the control diets and butyric acid (2 and 3%) supplemented diets up to the third week in their study.

The result of current experiment is however, contrary to the findings of earlier authors (Panda *et al.*, 2009; Taherpour *et al.*, 2009; Adil *et al.*, 2010; Adil *et al.*, 2011; Salmanzadeh, 2013). Panda *et al.* (2009) reported that butyric acid inclusion at 0.4 and 0.6% resulted in significant increase in body weight gain when compared to the control diet and 0.2% butyric acid inclusion level. However, Taherpour *et al.* (2009) reported an increase in final body weight (42

days) of chickens fed butyric acid supplemented diet when compared to those on the basal diet. The authors also reported a lower feed intake and feed conversion ratio for chickens on the butyric acid supplemented diet when compared those on supplement-free diet. Adil *et al.* (2010), it was concluded that butyric acid inclusion at 2 and 3% improved body weight gain and feed conversion efficiency in broiler chickens at 42 days. In another study, Adil *et al.* (2011) also reported a positive impact of butyric acid (2 and 3% inclusion rate) on body weight gain and feed conversion ratio at 42 days. Salmanzadeh (2013) reported a significant increase in body weight gain and feed conversion ratio in Japanese quail fed butyric acid supplemented diets (0.4, 0.5 and 0.6% inclusion rate). Agboola *et al.* (2015) reported an improved weight gain at 21 days when 0.4% organic acid was added to the broiler diets.

There appears to be more variability in detecting organic acid benefit when used as an additive in poultry production. The lack of consistency in demonstrating an organic acid benefit is worrying. While some researchers reported beneficial roles, others concluded that it had no beneficial effect on growth performance of chickens. In line with the result of the present study and contrary to those that reported positive effects, Hernandez *et al.* (2006) reported no beneficial effect on weight gain when formic acid was fed, as an additive, to broiler chickens. Esmailipour *et al.* (2011) also reported a non-significance in weight gain using citric acid. For fumaric acid, Biggs and Parsons (2008) concluded it had no beneficial effect on weight gain in broiler chicken. It can be concluded, in agreement with Yang *et al.* (2009) that the inconsistencies of reports on the effects of these feed additives on performance can be attributed to the variation in the level of acids used, variation in specific acid, variation in feed ingredient, management

practices, bird characteristics such as species, breeds, strains and prevailing environmental conditions. Therefore, the non-significant effects of additives in the current study could be attributed to one of the above-mentioned factors. It is also of note to observe the different nature of butyric acid used for the various studies. Butyric acid, salts of the acid, and butyric acid glycerides have all been used for the various experiments.

***Precaecal nutrient digestibility of broiler chicks fed antibiotics and butyric acid supplemented diets***

Improved precaecal digestibility of crude protein, ash and nitrogen free extract recorded in chickens fed diets containing antibiotics at 0.2, 0.3, 0.4 and 0.5%, respectively corroborates with the findings of Ao *et al.* (2009) who concluded that 2% citric acid supplemented diet in broiler chicken increased the retention of dry matter, crude protein and neutral detergent fibre. Similarly, Ghazala *et al.* (2011) reported that dietary 0.5% of either fumaric or formic acid and 0.75% of acetic or 2% citric acid improved crude protein, ether extract, crude fibre and nitrogen-free extract of broiler chickens. Moreover, Hernandez *et al.* (2006) and Garcia *et al.* (2007) reported that supplementation of formic acid (0.5%) in broiler finisher diet improved apparent ileal digestibility of dry matter (67.8%) and crude protein as compared with the control (56.4% DM and 60.7% CP) diet. This improvement in nutrient digestibility could be as a result of pH reducing ability of organic acids. According to Jongbloed *et al.* (2000), reduced pH in the upper part of the gastrointestinal tract may increase nutrient digestibility in diets. Due to reduced pH in the stomach, pepsinogen and other zymogens get activated by adjusting gastric acidity closer to that required for optimal activity resulting in increased enzyme

activity, improved digestion of proteins and possibly other nutrients as well.

Several researchers have demonstrated that dietary supplementation of organic acids improved the retention of protein and other nutrients (Mayer, 1994). Dietary supplementation with organic acid leads to increase in proliferation of beneficial bacteria such as Lactobacilli and Bifidobacter and selective elimination of pathogenic organism such as *E. coli* and *Salmonella spp* which compete with host for available nutrients (Partanen and Mroz, 1999). The growth inhibition of potential pathogenic bacteria in the gastrointestinal tract leads to better growth performance of animals. Also, observed improved nutrient digestibility with butyric acid supplementation in broiler chicks did not result in concomitant improvement in performance. However, Hernandez *et al.* (2006) did not observe any significant effect on nutrient digestibility. This inconsistency may be as a result of different nutritional composition of the diets as a result of varying ingredients used in the studies. The differences could also be due to change in the pH of feed, change in intestinal pH and digesta transit time, which may consequently affect nutrient utilization.

***Gut morphology of broiler chicks fed butyric acid supplemented diets***

Villus height, crypt depth and the ratio of villus height to crypt depth are considered as criteria to reflect the small intestine morphology and absorption capacity (Montagne *et al.*, 2003). Therefore, an increase in villus height, villus height to crypt depth ratio or decrease in the crypt depth is correlated with an improvement in the digestion and absorption of nutrients (Hou *et al.*, 2010; Yao *et al.*, 2012). Gut morphological indices like the villus height, villus length, crypt depth, villi width and epithelial thickness were

measured in the ileum of chicks across the treatments. For all the indices, there was no observable significant differences in their values across the dietary treatments. The result is not surprising as it is evident from the reported growth response parameters. It is expected and as stated by Xu *et al.* (2003) and Markovic *et al.* (2009), that the larger the villus height and length, the more the surface area available for nutrient absorption from the intestine, which will in turn result in a better growth and development of the host. In the current study, chickens on butyric acid supplemented diets had no higher villus height than those on the non-supplemented and antibiotics diet. This therefore perhaps justifies the no significant differences in growth performance observed. Lengthening of villi may increase total luminal villus absorptive area and subsequently result in satisfactory digestive enzyme action and higher transport of nutrients at the villus surface (Tufarelli *et al.*, 2010). The result is in agreement with the result of Adil *et al.* (2010) who observed that there was no significant difference in villus height in the ileum of chickens fed butyric acid supplemented diet and the non-supplemented control diet. The crypt is the region where stem cells divide for renewal of the villus; thus, the presence of a large crypt is reflective of fast tissue turnover and a high demand for tissue synthesis (Xia *et al.*, 2004). A deeper crypt may indicate faster tissue turnover to permit renewal of the villus, which suggests that the host's intestinal response mechanism is trying to compensate for normal sloughing or atrophy of villi due to inflammation from pathogens and their toxins (Gao *et al.*, 2008). Pelicano *et al.* (2005) also opined that pathogens cause disturbance in the normal microflora and intestinal epithelium thereby facilitating invasion and impairment in the ability to digest and absorb nutrients. This would lead to more

intestinal cell turnovers and a deeper crypt. Consequently, once these pathogens had been significantly reduced, a shallower depth of crypt is observed, which is indicative of a lower turnover and maintenance requirement which can finally lead to improve growth. The villus height: crypt depth ratio is a useful criterion for estimating the digestive capacity of the small intestine. A high villus height to crypt depth ratio indicates a decreased turnover of the intestinal mucosa. A slower turnover rate of the intestinal epithelium results in a lower maintenance requirement, which can finally lead to a higher growth rate or growth efficiency of the animal (Van Nevel *et al.*, 2005). Wu *et al.* (2004) reported that an increase in the villus height: crypt depth ratio is associated with better nutrient absorption, decreased secretion in the gastrointestinal tract, improved disease resistance, and faster growth.

#### ***Histopathology of the Ileum and liver of broiler chicks fed butyric acid supplemented diets***

The small intestine is the site of nutrient absorption in the gastrointestinal tract of the chicken, and as such any alteration in it could affect the bird's growth. A wide range of factors associated with diet, infectious disease agents, environment, and management practices can negatively affect the delicate balance among the components of the chicken gut and subsequently impair growth rate and feed conversion efficiency (Hughes, 2005). In this present study, clinical symptoms ranging from villi atrophy, necrosis of the villi, clubbing of the villi and loss of enterocyte were observed. This is indicative that the chickens might have been disease-challenged. No lesion was observed in the ileum of chickens on antibiotics and 0.3% butyric acid supplemented diet. The etiology of an enteric disease is complex, as combinations of viruses, bacteria, and other infectious



### ***Effect of butyric acid diets on performance and gut health of broiler chicken***

**Histopathological readings** Microscopic images displaying the histopathological observation of the ileum and liver are presented in the plates below.

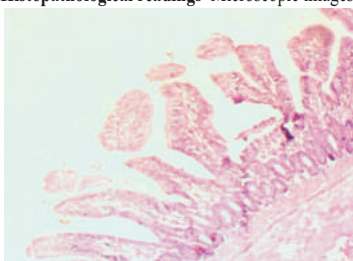


Plate 1: Showing sectioning of ileum of birds on the control diet. There was observed atrophy and clubbing of the villi

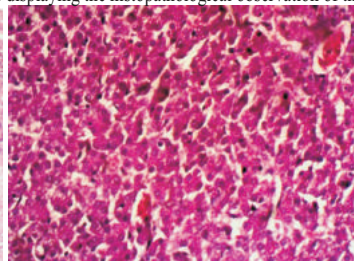


Plate 2: showing sample sectioning of liver of birds on the control diet. It shows mild diffuse hepatocellular atrophy and

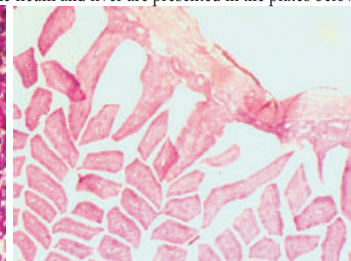


Plate 3: showing sample sectioning of ileum of birds on the antibiotic diet. No observable lesion was seen.

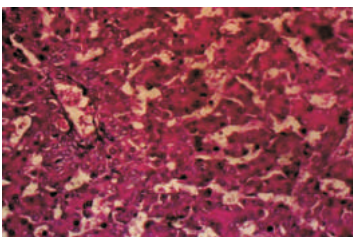


Plate 4: showing sample sectioning of liver of birds on antibiotic diet. Moderate hyperplasia of bile ductular epithelium

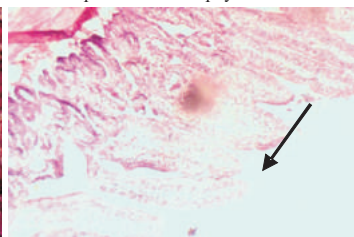


Plate 5: showing sample sectioning of ileum of birds on 0.1% butyric acid supplemented diet. It shows necrosis of villi enterocyte.

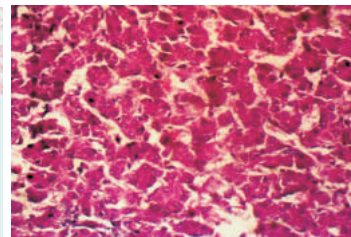


Plate 6: showing sample sectioning of liver of birds on 0.1% butyric acid). It shows slight hepatocellular atrophy.

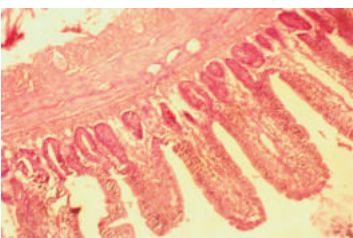


Plate 7: showing sample sectioning of ileum of birds on 0.2% butyric acid. Slight clubbing of villi was observed.

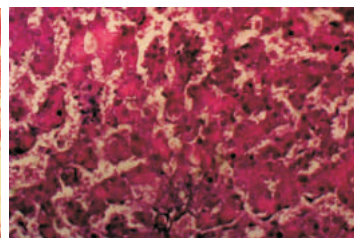


Plate 8: showing sample sectioning of liver of birds on 0.2% butyric acid. Moderate diffuse hepatocellular atrophy and accentuation of sinusoids was observed

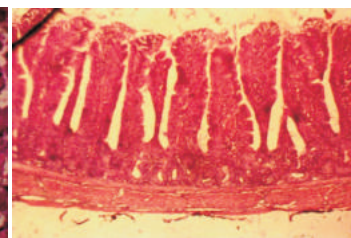


Plate 9: showing sample sectioning of ileum of birds on 0.3% butyric acid. No lesion was observed.

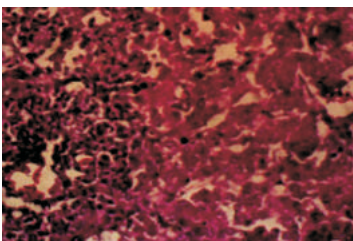


Plate 10: showing sample sectioning of liver of birds on 0.3% butyric acid. Hepatocellular necrosis and inflammation was observed.

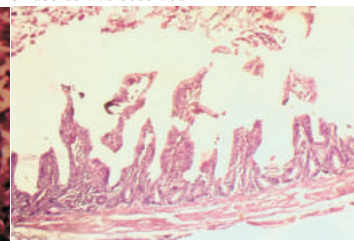


Plate 11: showing sample sectioning of ileum of birds on 0.4% butyric acid. Villi atrophy and loss of enterocyte was observed.

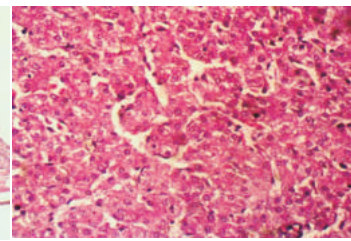


Plate 12: showing sample sectioning of liver of birds on 0.4% butyric acid. Hepatocellular necrosis was observed in the liver.

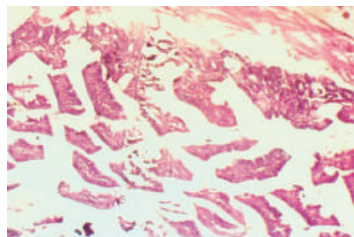


Plate 13: showing sample sectioning of ileum of birds on treatment 7 (0.5% butyric acid). Villi atrophy and hepatocellular necrosis was observed.

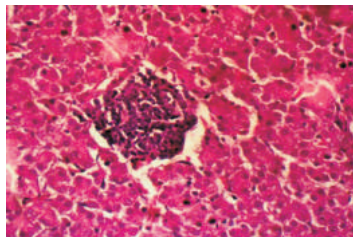


Plate 14: showing sample sectioning of liver of birds on 0.5% butyric acid. Focus of lymphoid aggregate in parenchyma of liver.

and non-infectious agents may be involved (Reynolds, 2003). The lesions of necrotic enteritis can be among the most severe of any disease that occurs in the chicken intestine (Long *et al.*, 1974). Damage to the intestinal tract by pathogens may cause poor feed conversion efficiency and reduced body weight gains in chicken. As observed by Fernández-Rubio *et al.* (2009), butyric acid can be used to protect chicken from *Salmonella enteritis* infection. Sunkara *et al.* (2011) also opined that butyrate enhanced disease resistance in chicken by inducing antimicrobial host defense peptide (HDP) gene expression. Their result indicated that feed supplementation with 0.1% butyrate led to a significant increase in HDP gene expression in the intestinal tract of chicken. The liver performs variety of functions and plays important role in metabolic processes in chickens. It is frequently affected by various infectious agents, toxic substances and systemic disease processes and the resultant pathological changes are expressed as hepatosis, necrosis, fatty liver, hepatitis, cholangitis *e.t.c.* Many instances such lesions and the pattern of changes in this organ are of great value in diagnosis of poultry diseases (Parimala, 2003). In the present study, liver of chickens from all treatments was observed pathologically and found to show various disease symptoms. Hepatocellular atrophy and necrosis, hyperplasia of bile ductular epithelium, accentuation of sinusoids, and focus of lymphoid aggregate in parenchyma of liver were observed. Chickens on the conventional antibiotics diet showed moderate hyperplasia of bile ductular epithelium. It has been suggested that there is a positive correlation between the incidence of necrotic enteritis and liver lesion in chickens. The work of LÖvland and Kaldhusdal (1999) concluded that the occurrence of necrotic enteritis in broiler flocks may be monitored by using meat

inspection data on liver lesions. Necrotic enteritis may emerge as a problem in countries with intensive poultry production if the use of antibacterial compounds in feed becomes restricted (LÖvland and Kaldhusdal, 1999). Bile ductule hyperplasia is one of the symptoms associated with *Clostridium perfringens* infection (Hutchison and Riddell, 1990) and necrotic enteritis in broilers may arise when changes in the gut microecology allow colonization of *Clostridium perfringens* type A or C in the small intestine (Ficken and Wages, 1997). It is evident that the chickens were challenged with disease which might have taken a toll on their performance.

### **Conclusion**

The study showed that at 21 days, butyric acid inclusion, up to 0.5% had no significant effect on growth parameters and gut morphological characteristics. Therefore, using butyric acid up to 0.5% in diet can replace antibiotics usage but might not have any comparative beneficial effect on productivity of broiler chickens at 21 days.

### **References**

- Adil, S., Banday, M. T., Ahmad, G., Masood, B., Mir, S. and Rehman, M. 2010. Effect of dietary supplementation of organic acids on performance, intestinal histomorphology, and serum biochemistry of broiler chicken. *Veterinary Medicine International* Volume, Article ID 479485, 7 pp.
- Adil, S., Banday, M. T., Bhat, G. A., Qureshi, S. D. and Wani, S. A. 2011. Effect of supplemental organic acids on growth performance and gut microbial population of broiler chicken. *Livestock Research for Rural Development* 23 (1): 1-8.
- Agboola, A. F., Omidwura, B. R. O., Odu, O., Adeyemi, W. T., Suberu,

- S. A. and Aroniyo, I. 2014.** Influence of dietary supplementation of probiotics and symbiotics on growth performance, nutrient digestibility and organ weights in turkey poults. *Ibadan Journal of Agricultural Research*. 10(10): 1-11.
- Agboola, A. F. 2011.** Precaecal digestible crude protein and amino acids in some conventional feedstuffs in broiler starter diets. *PhD thesis*, Department of Animal Science, University of Ibadan; pp 52.
- Agboola, A. F., Omidwura, B. R. O., Odu, O., Popoola, I. O. and Iyayi, E. A. 2015.** Effects of organic acid and probiotic on performance and gut morphology in broiler chickens. *South African Journal of Animal Science* 45 (5): 494-501.
- Aghazadeh, A.M. and TahaYazdi, M. 2012.** Effect of butyric acid supplementation and whole wheat inclusion on the performance and carcass traits of broilers. *South African Journal of Animal Science* 42:3.
- Alp, M., Kocabagli, N. and Kahraman, R. 1999.** Effect of dietary supplementation with organic acid and zinc bacitracin on ileal microflora, pH and performance in broilers. *Turk. J. Vet. Anim. Sci.*, 23: 451-455.
- Ao, T., Cantor, A. H., Pescatore, A. J., Ford, M. J., Pierce, J. L. and Dawson, K. A. 2009.** Effect of enzyme supplementation and acidification of diets on nutrient digestibility and growth performance of broiler chicks. *Poultry Science*, 88(1):111-117.
- AOAC. 2000.** Association of Official Analytical Chemists Official methods of analysis. *16th ed.* Arlington, V.A., USA.
- Biggs, P. and Parsons, C. M. 2008.** The effects of several organic acids on growth performance, nutrient digestibilities, and cecal microbial populations in young chicks. *Poult Sci*; 87(12): 2581-2589.
- Dibner, J. J. and Buttin, P. 2002.** Use of organic acids as a model to study the impact of gut microflora on nutrition and metabolism. *J Appl Poultry Res*; 11:453-463.
- Esmacilipour, O., Shivazad, M., Moravej, H., Aminzadeh, S., Rezaian, M., van Krimpen, M. M. 2011.** Effects of xylanase and citric acid on the performance, nutrient retention, and characteristics of gastrointestinal tract of broilers fed low-phosphorus wheat-based diets. *Poult Sci*; 90:1975-1982.
- Fernandez-Rubio, C., Ordonez, C., Abad-Gonzalez, J., Garcia-Gallegos, A., Pilar Honrubia, M., Jose, J. Mallo, R. and Balaña-Fouce. 2009.** Butyric acid-based feed additives help protect broiler chickens from *Salmonella* Enteritidis infection. *Poultry Science*, 88(5):943-948
- Ficken, M.D. and Wages, D.P. 1997.** Necrotic enteritis. In: Diseases of Poultry, 10th edn. (Calnek, B.W., Barnes, H.J., Beard, C.W., McDougald, L.R. and Saif, Y.M., Eds.), Mosby-Wolfe, Ames, IA. 261 - 264.
- Gao, J., Zhang, H. J., Yu, S. H., Wu, S. G., Yoon, I., Quigley, J., Gao, Y. P. and Qi, G. 2008.** Effects of yeast culture in broiler diets on performance and immunomodulatory functions. *Poult. Sci.* 87:1377 - 1384.
- Garcia, V., Catala-Gregori, P., Hernandez, F., Megias, M. D. and Madrid, J. 2007.** Effect of formic



- acid and plant extracts on growth, nutrient digestibility, intestine mucosa morphology, and meat yield of broilers. *Journal of Applied Poultry Research*, 16(4):555-562.
- Garrido, M.N., Skjervheim, M., Oppeggaard, H. and Sorum, H. 2004.** Acidified litter benefits in the intestinal flora balance of broiler chicken. *Application Environment Microbiology* 70: 5208-5213
- Ghazalah, A. A., Atta, A. M., Elkloub, K., Moustafa, M. E. L. and Riry, F. H. S. 2011.** Effect of dietary supplementation of organic acids on performance, nutrients digestibility and health of broiler chicks. *International Journal of Poultry Science*, 10(3), 176-184.
- Gunal, M., Yayli, G., Kaya, O., Karahan, N. and Sulak, O. 2006.** The effects of antibiotic growth promoter, probiotic or organic acid supplementation on performance, intestinal microflora and tissue of broilers. *Int J Poult Sci.*, 5:149-55.
- Hassan, H. M. A., Mohamed, M. A., Youssef, A.W. and Hassan, E. R. 2010.** Effect of using organic acids to substitute antibiotic growth promoters on performance and intestinal microflora of broilers. *Asian-Aus Journal of Animal Science*. 23(10):1348-1353.
- Hernandez, F., Garcia, V., Madrid, J., Orengo, J., Catalá, P. and Megias, M. D. 2006.** Effect of formic acid on performance, digestibility, intestinal histomorphology and plasma metabolite levels of broiler chickens. *British Poultry Science*, 47(1), 50-56.
- Hou, Y., Wang, L. and Ding, B. 2010.** Dietary alpha-ketoglutarate supplementation ameliorates intestinal injury in lipopolysaccharide-challenged piglets. *Amino Acids*, 39(2): 555-564.
- Hughes, R. J. 2005.** An integrated approach to understanding gut function and gut health of chickens. *Asia Pac. J. Clin. Nutr.* 14:S27.
- Hutchison, T.W.S. and Riddell, C. 1990.** A study of hepatic lesions in broiler chickens at processing plants in Saskatchewan. *Can. Vet. J.* 31, 20 - 25.
- Iji, P.A., Hughes, R.J., Choct, M. and Tivey, D.R. 2001.** Intestinal structure and function of broiler chickens on wheat based diets supplemented with a microbial enzyme. *Asian-Australian J. Anim. Sci.* 14:54-60.
- Jongbloed, A. W., Mroz, Z., Van der Weij-Jongbloed, R. and Kemme, P. A. 2000.** The effects of microbial phytase, organic acids and their interaction in diets for growing pigs. *Livestock Production Science*, 67(1-2), 113-122.
- Kritas, S.K. and Morrison, R.B. 2005.** Evaluation of probiotics as a substitute for Antibiotics in a large pig nursery. *Vet. Rec.* 156: 447-448.
- Kumar, S., Eren, U., Onol, A. G. and Sandicki, M. 2010.** Effects of dietary organic acid supplementation on growth performance in the intestinal mucosa of broilers. *Journal of Poultry Science*. 10: 463-468.
- Lesson, S., Namkung, H., Antongiovanni, M. and Lee, E. H. 2005.** Effect of Butyric Acid on the Performance and Carcass Yield of Broiler Chickens. *J. Poultry Science* 84:1418-1422
- Lesson, S. 2007.** Butyrate lancing science versus societal issues in poultry nutrition. *Nutr Abstr Rev*; 71:1-5.
- Long, J. R., Pettit, J. R. and Barnum, D.**



- A. 1974. Necrotic enteritis in broiler chickens. II. Pathology and proposed pathogenesis. *Can. J. Comp. Med.* 38:467–474.
- LÖvland, A. and Kaldhusdal, M. 1999. Liver lesions seen at slaughter as an indicator of necrotic enteritis in broiler flocks. / *FEMS Immunology and Medical Microbiology*. 24: 345–351.
- Mahdavi, R. and Torki, M. 2009. Study on Usage period of protected Butyric Acid on performance, carcass characteristics, serum metabolite levels and Humora Immune response of broiler chickens. *Journal of Animal and Veterinary Advances*. 8(9):1702–1709.
- Markovic, R., Šefer, D., Krstic, M. and Petrujkic, B. 2009. Effect of different growth promoters on broiler performance and gut morphology. *Arch. Med. Vet.*, 41 : 163 – 169.
- Mayer, E. A. 1994. The physiology of gastric storage and emptying. In: physiology of the gastrointestinal Tract. 3rd ed. New York: Lippincott Raven Press, 929–76
- Montagne, L., Pluske, J. R. and Hampson, D. J. 2003. A review of interactions between dietary fibre and the intestinal mucosa, and their consequences on digestive health in young non-ruminant animals. *Anim Feed Sci Technol.*; 108(1-4): 95–117.
- NRC (National Research Council) 1994. Nutrient Requirements of Poultry. National Academy Press: Washington. DC. 9th ed. Pp. 35–39.
- Panda, A.K., Raju, M.V.L.N., Rama, Rao. S.V., Shyam Sunder G. 2009b. Effect of Butyric Acid on Performance, Gastrointestinal Tract Health and Carcass Characteristics in Broiler Chickens. *Asian-Aust. J. Anim. Sci.* Vol. 22, No. 7 : 1026 – 1031.
- Panda, A.K., Raju, M.V., Rama, L. N., Rao. S.V., Shyam Sunder G. and Reddy, M. R. 2009. Effect of graded levels of formic acid on gut microflora count, serum biochemical parameters, performance, and carcass yield of broiler chickens. *Indian J. Anim. Sci.* 79:1165–1168.
- Parimala D.M. 2003 “Studies on the pathology of liver lesions in chicken”. Thesis submitted to the Department of Pathology, College of Veterinary Science, Tirupati Acharya n.g. Ranga Agricultural University.
- Partanen, K. H., and Mroz, Z. 1999. Organic acids for performance enhancement in pig diets. *Nutrition Research Reviews*, 12(1), 117–145.
- Pelicano, E. R. L., Souza, P. A., Souza, H. B. A., Figueiredo, D. F., Boiago, M. M., Carvalho, S. R. and Bordon, V. F. 2005. Intestinal mucosa development in broiler chickens fed natural growth promoters. *Rev. Bras. Cienc. Avic.* vol. 7 no.4
- Reynolds, D. L. 2003. Multicausal enteric diseases. In Diseases of Poultry. Y. M. Saif, (ed). Iowa State University Press, Ames. 1169–1171.
- Salmanzadeh, M. 2013. Evaluation of dietary butyric acid supplementation on small intestinal morphology, performance and carcass traits of Japanese quails. *Revue Méd. Vét.*, 164(10):481–485.
- Sunkara, L. T., Achanta, M., Schreiber, N. B., Bommineni, Y. R. and Dai, G. 2011. Butyrate Enhances Disease Resistance of Chickens by Inducing Antimicrobial Host Defense Peptide Gene Expression. *PLoS ONE* 6(11): e27225.
- Taherpour, K., Moravej, H., Shivazad, M., Adibmoradi, M., and Yakhchali, B. 2009. Effects of

- dietary probiotic, prebiotic and butyric acid glycerides on performance and serum composition in broiler chickens. *African Journal of Biotechnology* Vol. 8 (10), pp. 2329–2334.
- Tufarelli, V., Desantis, S. Zizza, S. and Laudadio, V. 2010.** Performance, gut morphology, and carcass characteristics of fattening rabbits as affected by particle size of pelleted diets. *Arch. Anim. Nutr.* 64:373–382.
- Van den Bogaard, A.E. and Stobberingh, E. E. 1999.** Antibiotic usage in animals. *Drugs.* 58: 589–607
- Van Immerseel F., Russell J. B., Flythe M. D., Gantois I., Timbermont L., Pasmans F., Haesebrouck F. and Ducatelle R. 2006.** The use of organic acids to combat salmonella in poultry: a mechanistic explanation of the efficacy. *Avian Pathol.* 35:182–188.
- Van Nevel, C. J., Decuypere, J. A., Dieric, N. A. and Moll, K. 2005.** Incorporation of galactomannans in the diet of newly weaned piglets: Effect on bacteriological and some morphological characteristics of the small intestine. *Arch. Anim. Nutr.* 59 : 123–138.
- Wu, Y. B., V. Ravindran, D. G. Thomas, M. J. Birtles, and W. H. Hendriks. 2004.** Influence of method of whole wheat inclusion and xylanase supplementation on the performance, apparent metabolisable energy, digestive tract measurements and gut morphology of broilers. *Br. Poult. Sci.*, 45: 385–394.
- Xia, M. S., Hu, C. H. and. Xu Z. R. 2004.** Effects of copper-bearing montmorillonite on growth performance, digestive enzyme activities, and intestinal microflora and morphology of male broilers. *Poult. Sci.* 83:1868–1875.
- Xu, Z. R., Hu, C. H., Xia, M. S., Zhan, X. A. and Wang, M. Q. 2003.** Effects of dietary fructooligosaccharide on digestive enzyme activities, intestinal microflora and morphology of male broilers. *Poult Sci.*, 82:1030–6.
- Yang, Y., Iji, P. A. and Choct, M. 2009.** Dietary modulation of gut microflora in broiler chickens: A review of the role of six kinds of alternatives to in-feed antibiotics. *World's Poult. Sci. J.* 65:97–114.
- Yao, K, Yin, Y., Li, X, 2012.** Alpha-ketoglutarate inhibits glutamine degradation and enhances protein synthesis in intestinal porcine epithelial cells. *Amino Acids*, 42(6): 2491–2500.

*Received: 16<sup>th</sup> July, 2019*

*Accepted: 19<sup>th</sup> December, 2019*

## Erratum

The paper titled “ **Influence of butyric acid supplemented diets on growth response, precaecal nutrient digestibility, gut morphology and histopathological measurements in broiler chickens**” by Agboola, A. F., Omidwura, B. R. O., Ahmed, R. O. and Ayoola, O. D. previously published in Volume 46:4 of Nigerian Society of Animal Production Journal has been withdrawn due to technical error and rfepublished in Volume 47: Issue 4 as “ **Influence of butyric acid supplemented diets on growth response, precaecal nutrient digestibility, gut morphology and histopathological measurements in broiler chickens**” by Agboola, A. F., Omidwura, B. R. O., Ahmed, R. O. and Ayoola, O. D